

Concurrent use of Collagen* and NPWT** for Compromised Surgical Wounds

Matthew Ellis, MD. Wound Therapy Services, NFRMC, Gainesville, FL 32605

CS-066

Introduction:

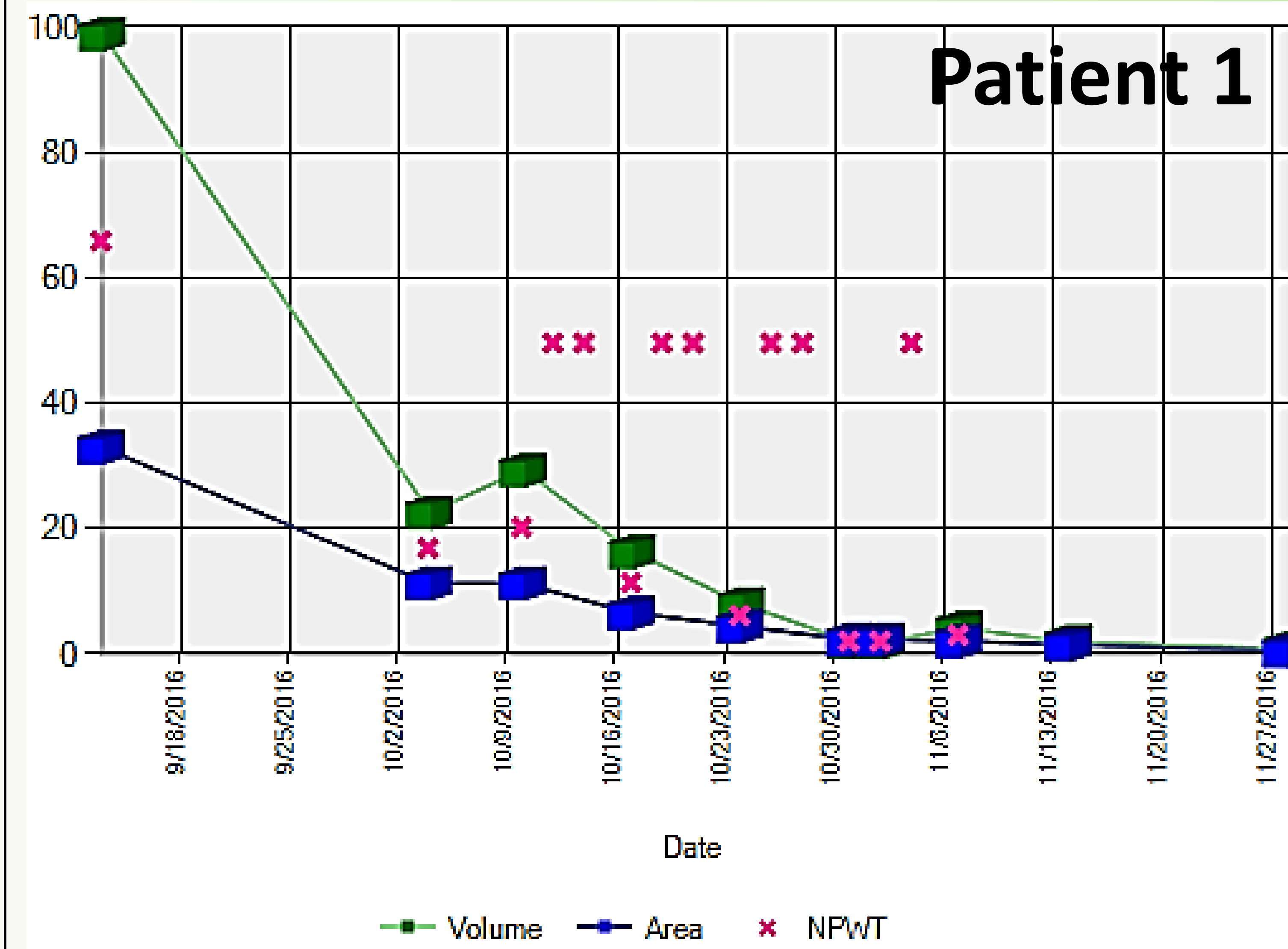
Wounds involving soft tissue and bone present a particular clinical challenge in light of the severe risks and complications they pose. We assessed the value of combining negative pressure wound therapy (NPWT) and collagen at point of use in healing wounds in two high risk patients with post-operative wound dehiscence that was unresponsive to standards of care.

Results:

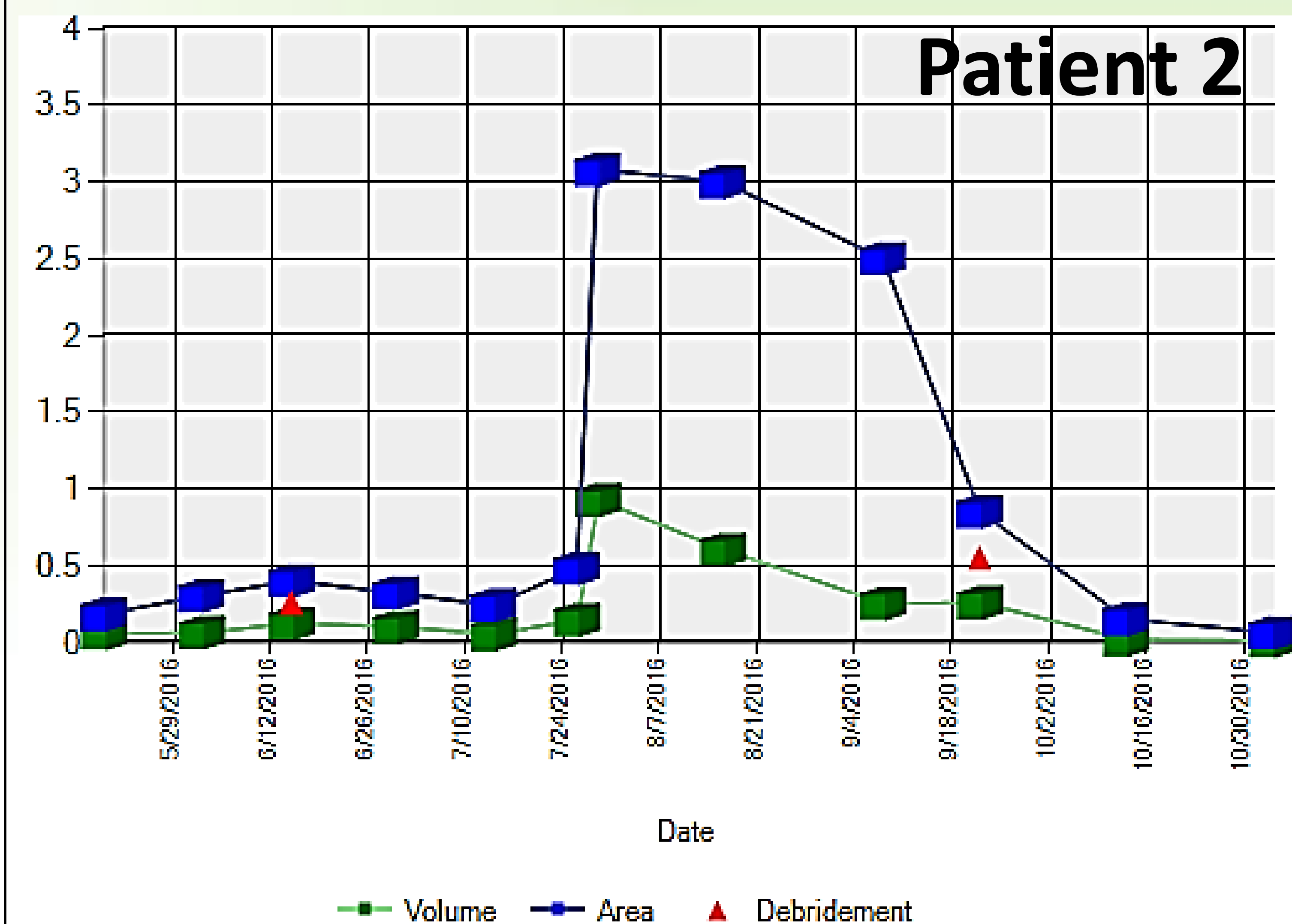
While neither wounds responded to stand alone NPWT or standard dressings, reductions of ~80% in wound sizes were seen by week 3 when used in conjunction. Complete granulation occurred around 11-12 wks (see wound healing summary).

Discussion:

The availability of a novel stabilized collagen wound matrix* enabled concurrent use with NPWT**. The physico-chemical attributes of this collagen matrix* was crucial to the successful clinical outcome seen. Additional evaluation of this combination approach as a medical-economic alternate for managing complex wounds is warranted.

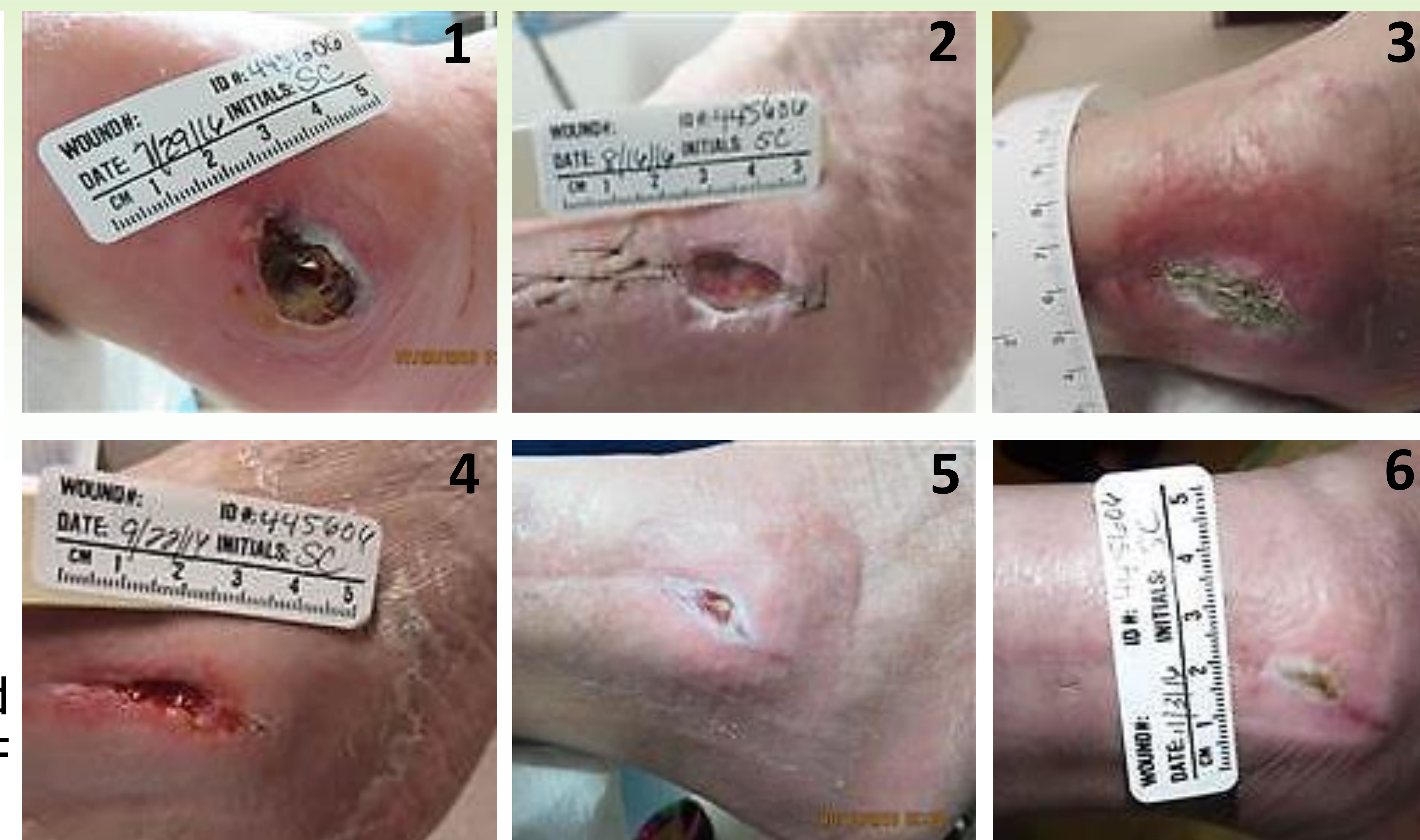
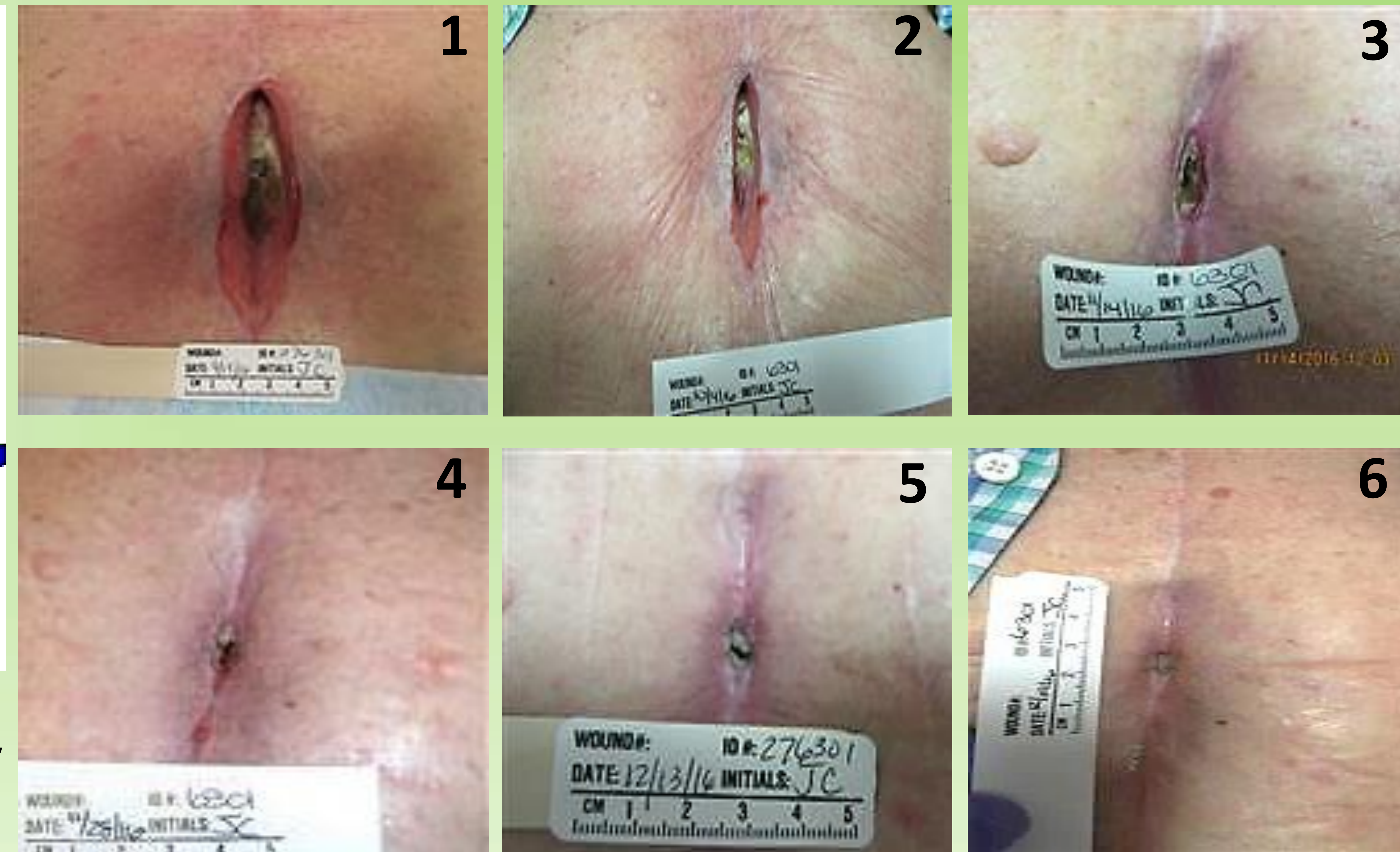


Case 1: dehisced mediastinal surgical wound (10.3cm x 3.2cm x 3cm) post 3V CABG procedure (unresponsive >2mo).




Case 2: dehisced surgical site wound over right lateral malleolus after an ORIF fracture repair (unresponsive ~5mo).

Wound Healing Summary



* bio-ConneKt Wound Matrix by MLM Biologics Inc., FL.
** VAC Simplicity NPWT by Acelity, TX.



MLM Biologics Inc.

MLM Biologics Inc.,
12085 Research Drive, Alachua, FL-32615.
www.mlmbiologics.com
1-844-4-MLM-BIO